

# Myokardiale Gefäßversorgung in der Echokardiografie

**Merke:**

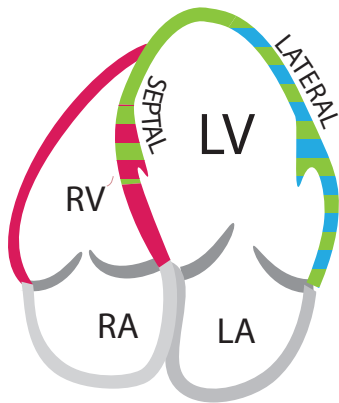
**Lindgrün LAD**

**Rot RCA**

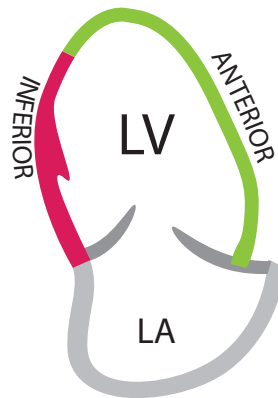
**Cyan CX**

## Transthorakale Echokardiografie

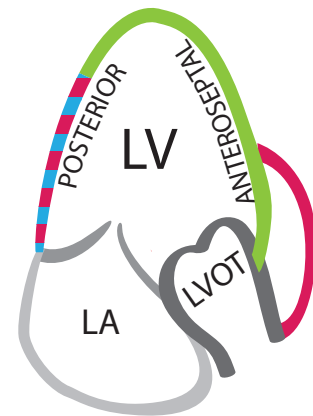
4-Kammer-Blick



2-Kammer-Blick



3-Kammer-Blick



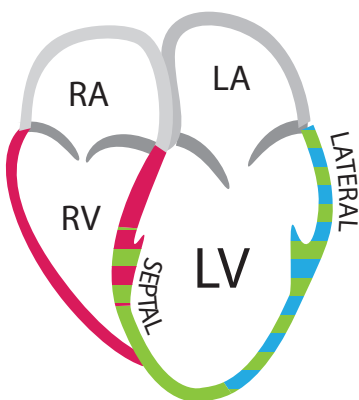
LAD  
LAD / CX

RCA  
RCA / LAD

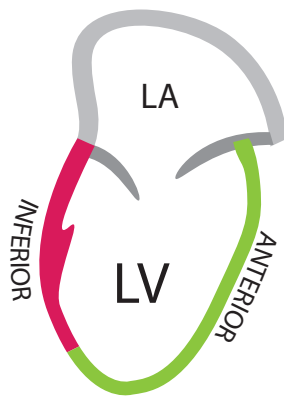
RCX  
RCA / CX

## Transösophageale Echokardiografie

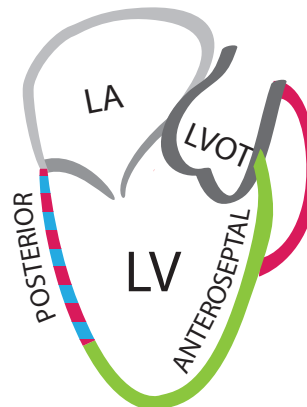
ME 4C



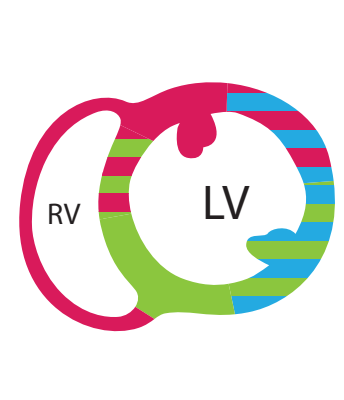
ME LAX



ME 2C



TG Mid SAX



LAD  
LAD / CX

RCA  
RCA / LAD

RCX  
RCA / CX

